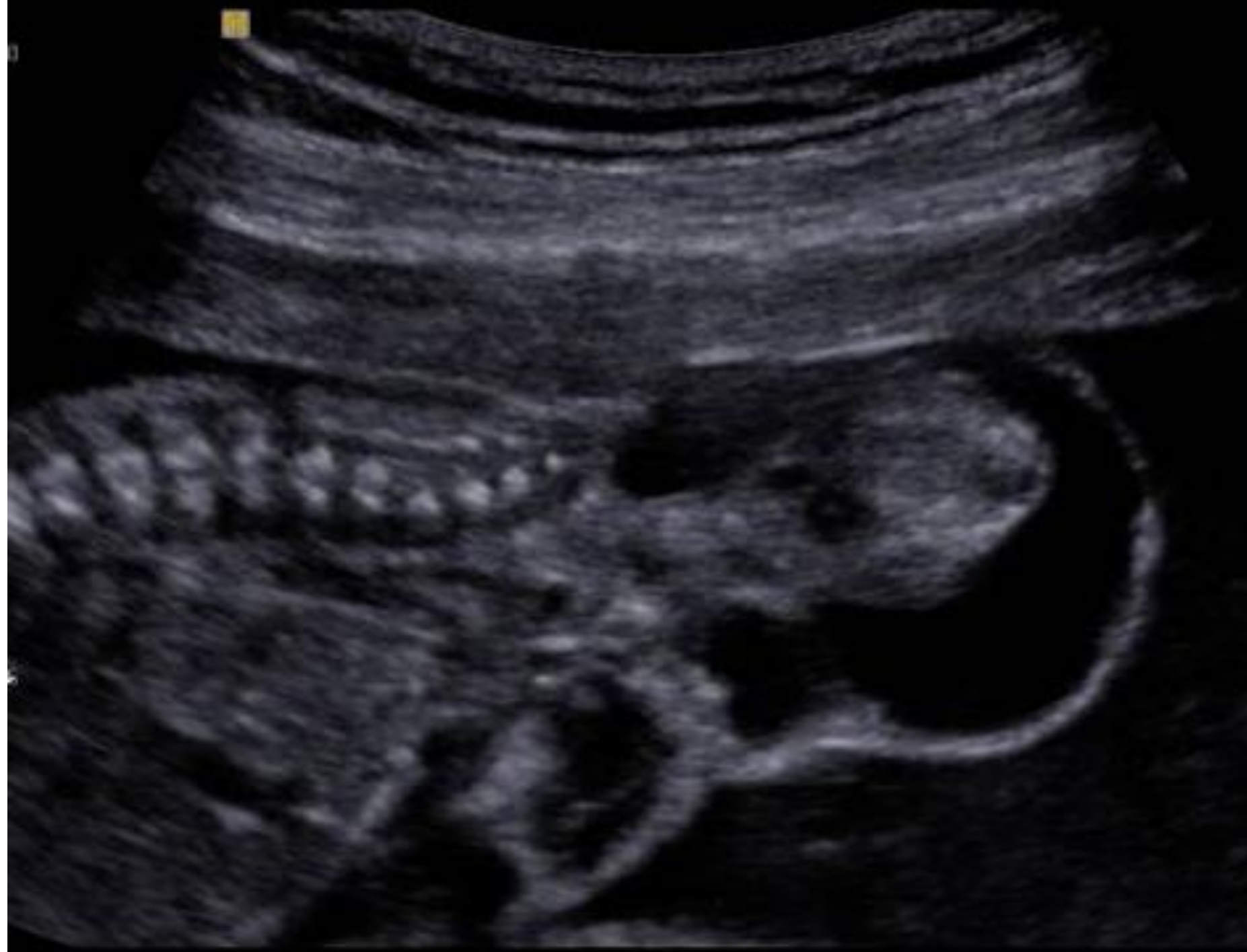

# HKSUM CME activity (Oct 2009)

Sponsored by Medison company

# Case

- Ultrasonography at 20 weeks' gestation



M

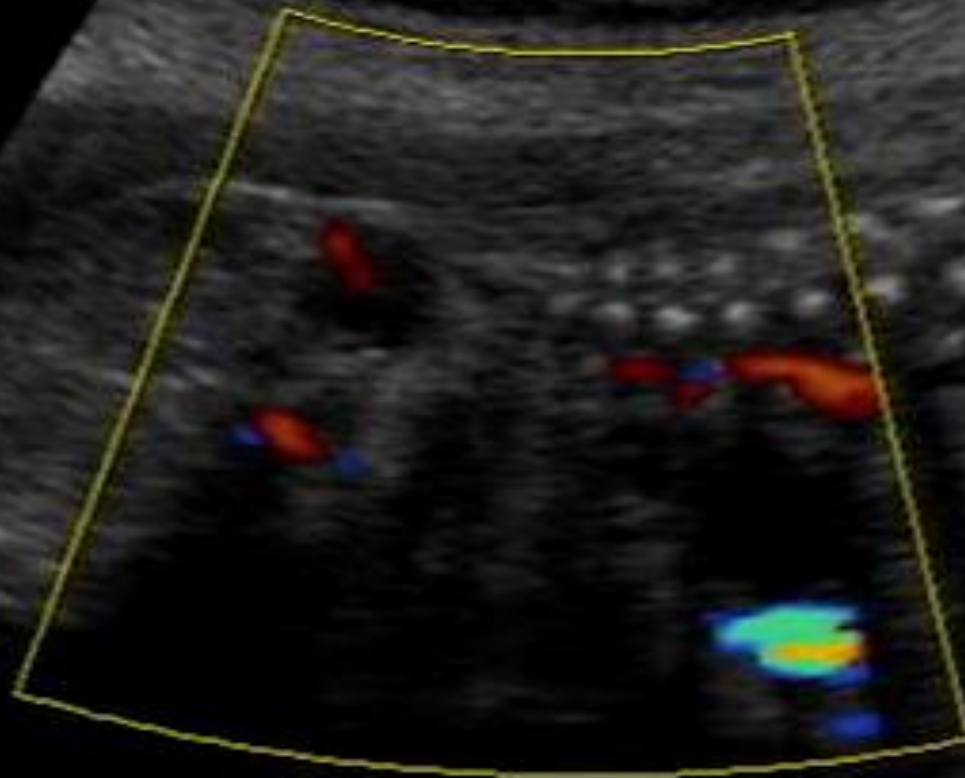
[2D] G50 / 100dB

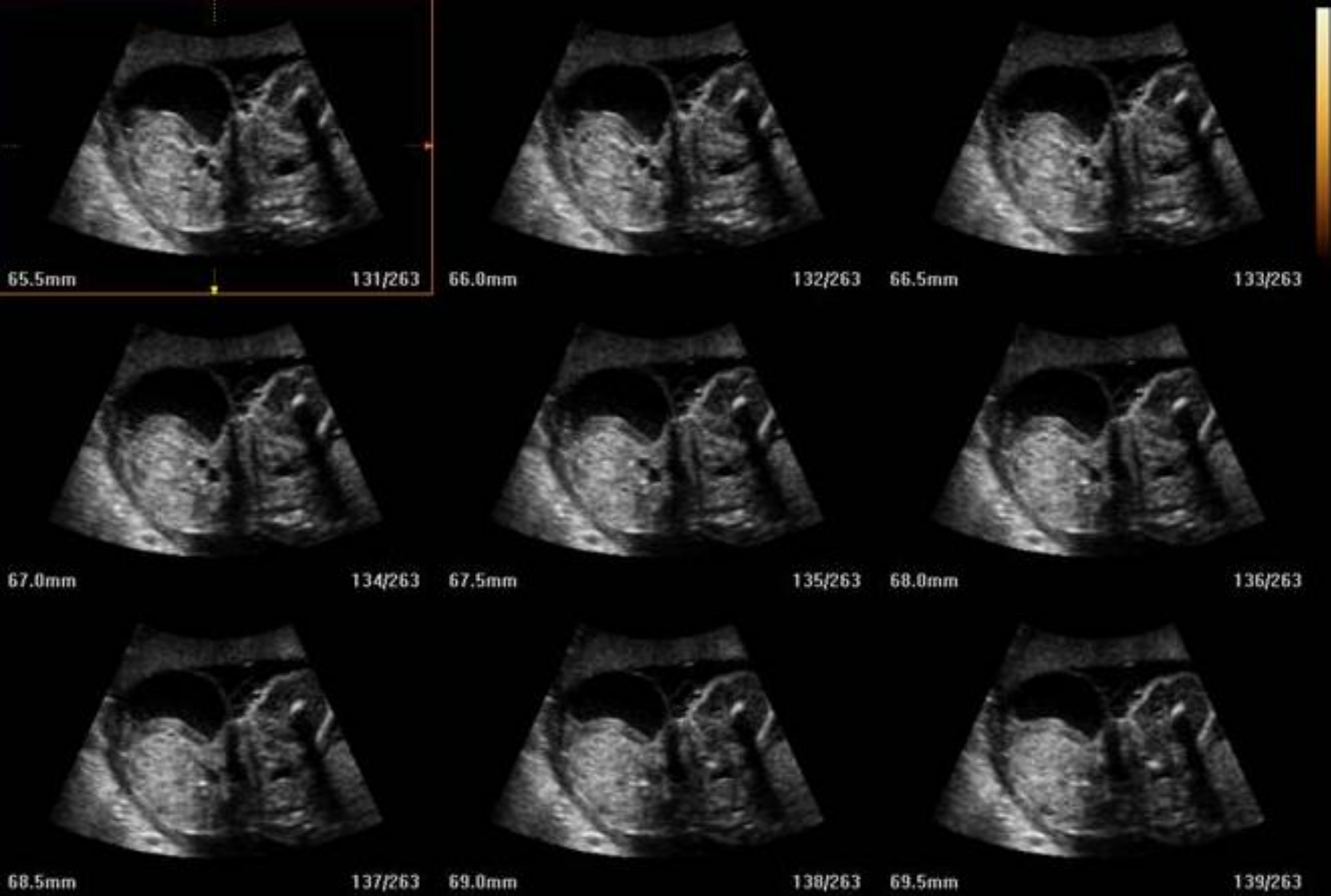FA10 / P90

HAR / FS12

[C] G40 / 2.50 kHz

FA5 / F1 / 13





# Questions

- 1. What is the likely diagnosis?
- 2. What is the differential diagnosis?
- 3. What are the prognostic factors?
- 4. What complications would you look out for?