

HKSUM CME program

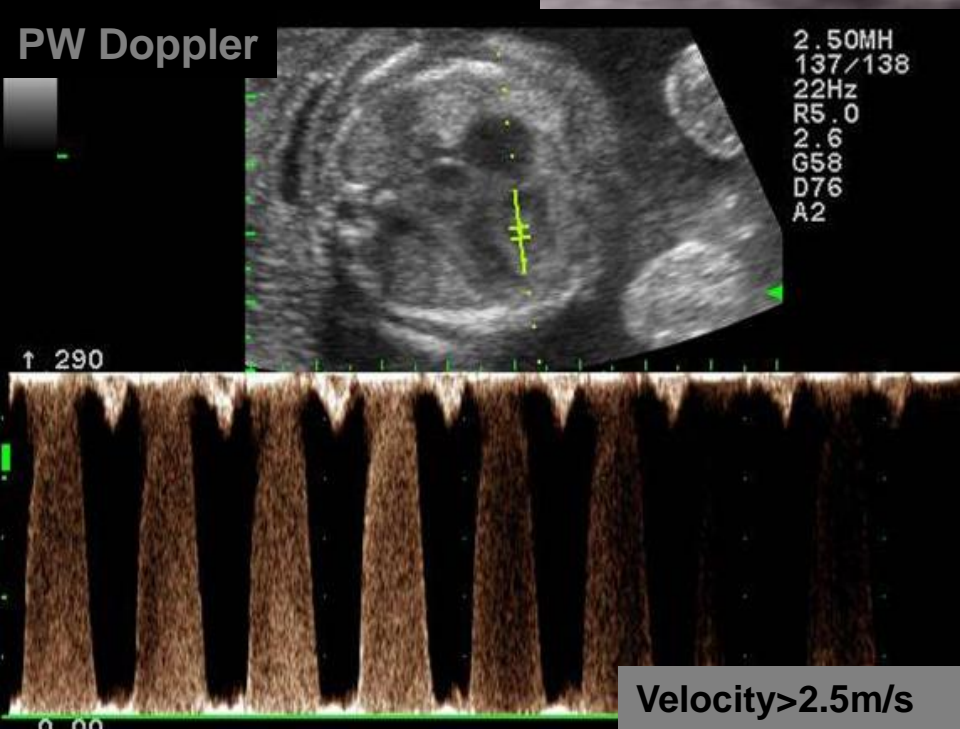
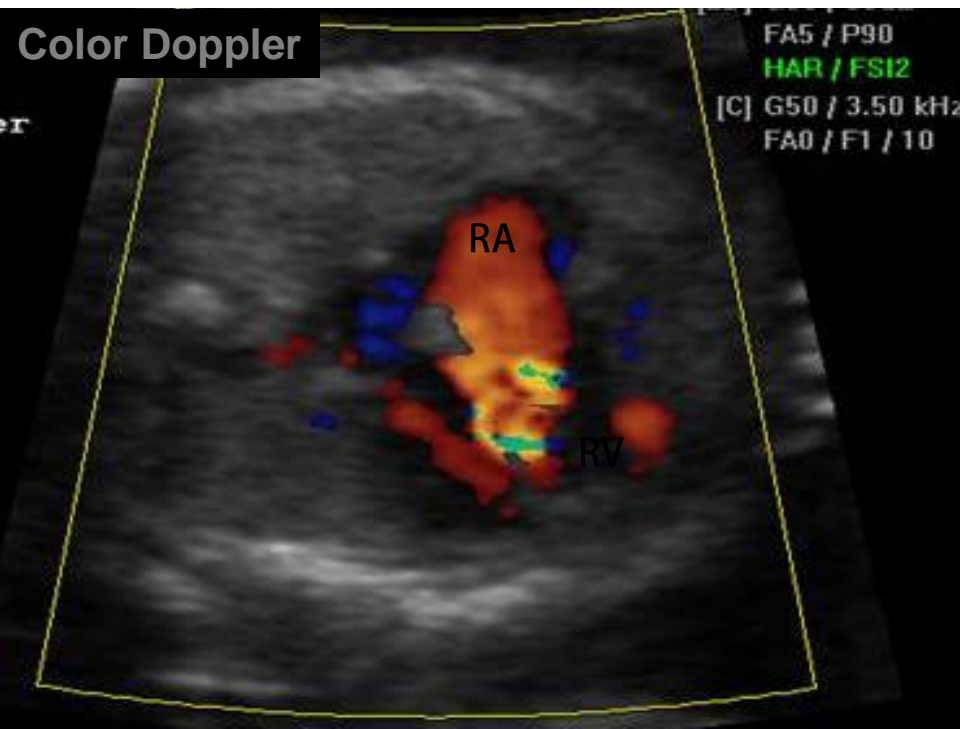
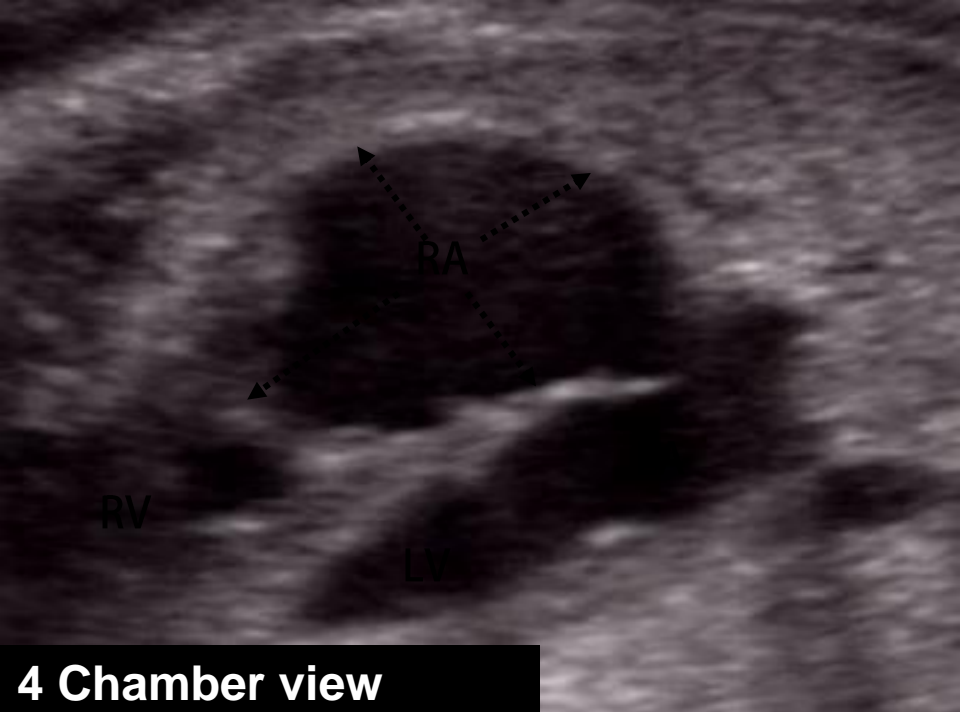November 2009

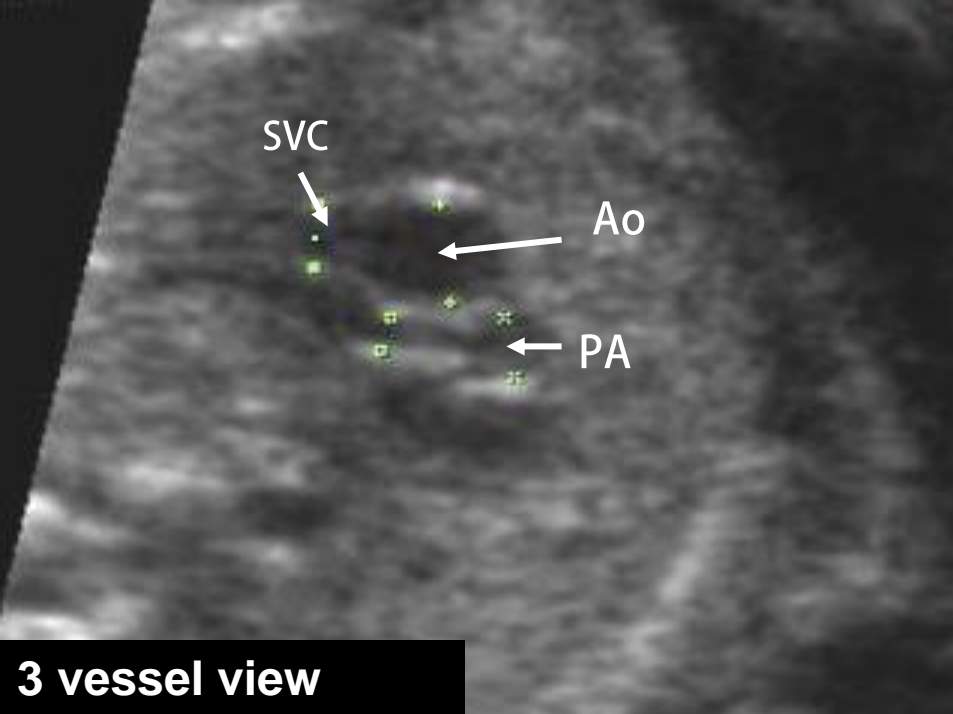
Acknowledgement: Hye-Sung Won M.D

**Department of Obstetrics and Gynecology
University of Ulsan College of Medicine,
Asan Medical Center, Seoul, Korea**

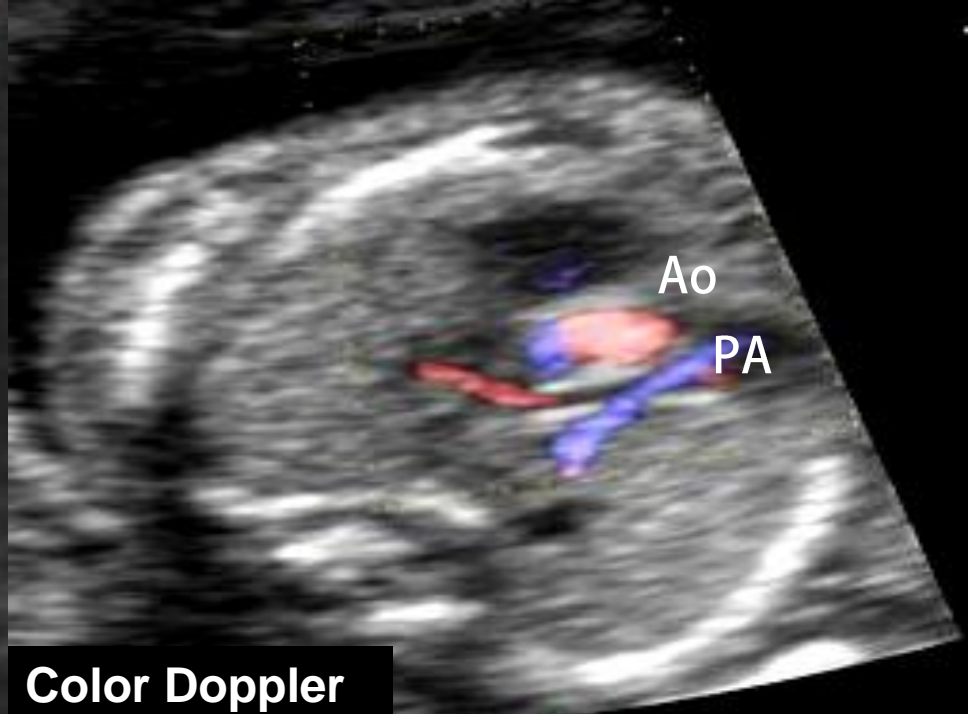
Case

Anomaly scan at 20 weeks' gestation

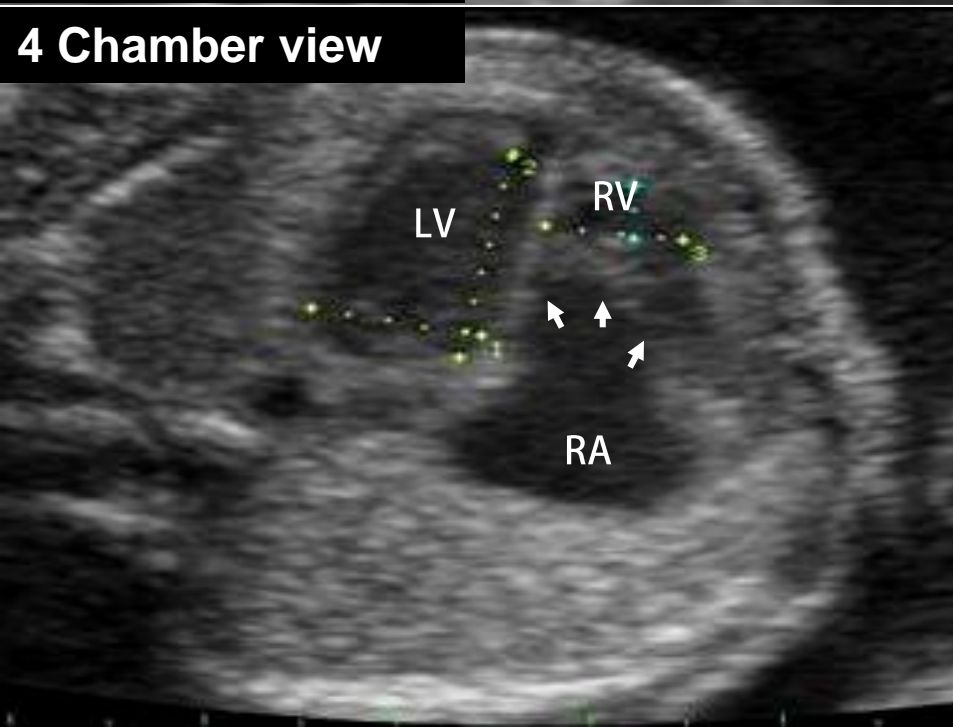




3 vessel view



Color Doppler

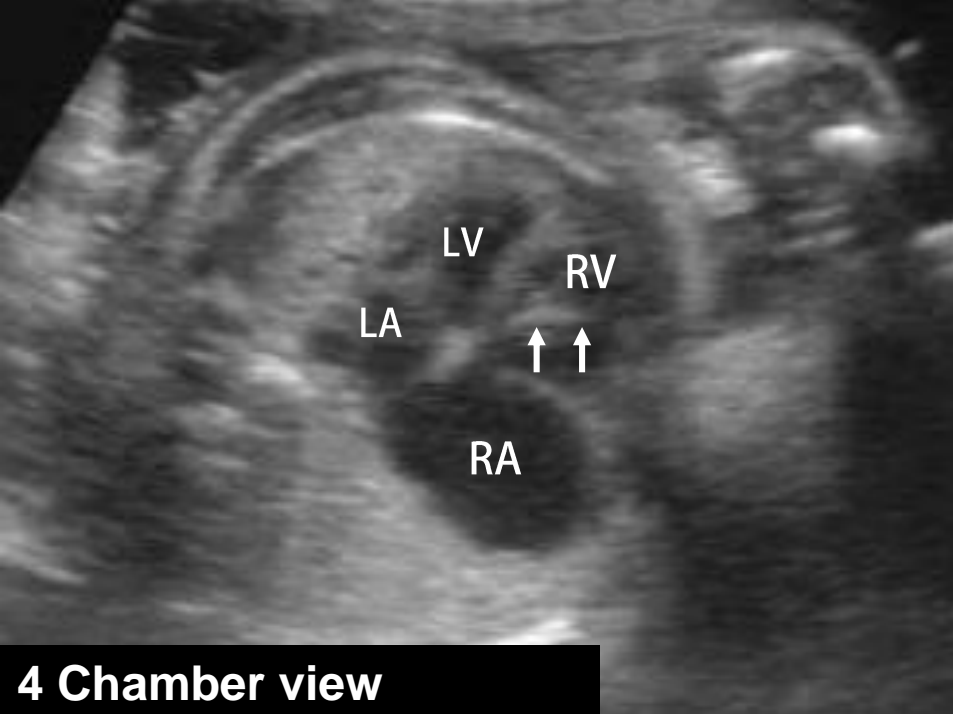


4 Chamber view

Right atrium size: 10.6*14.0mm

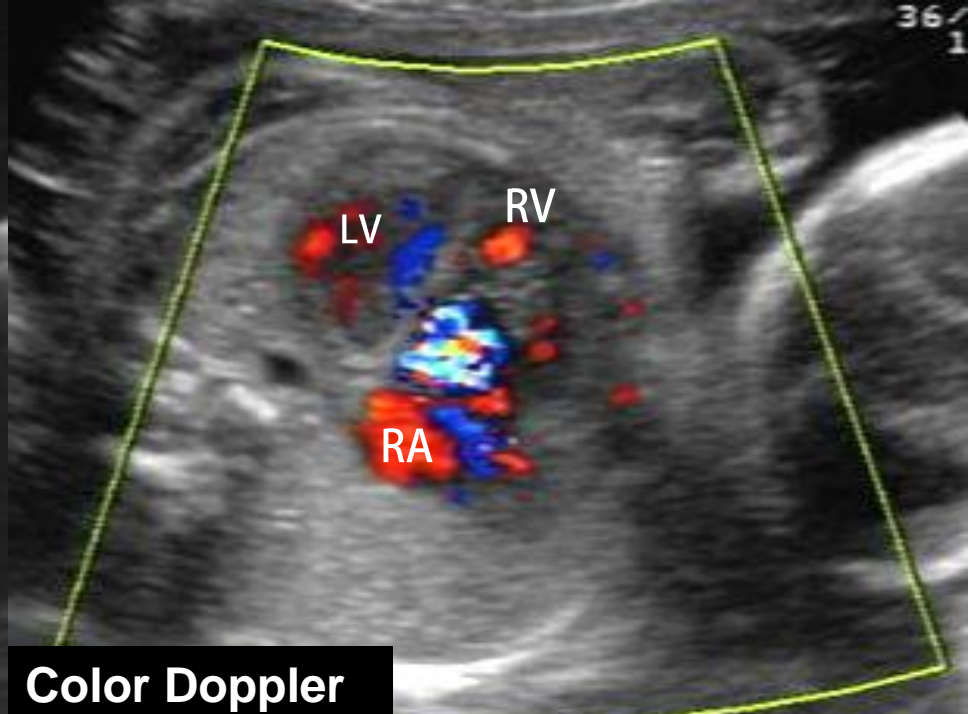
Pulmonary artery:
size : 2.5mm, laminar flow

Cordocentesis : normal karyotype

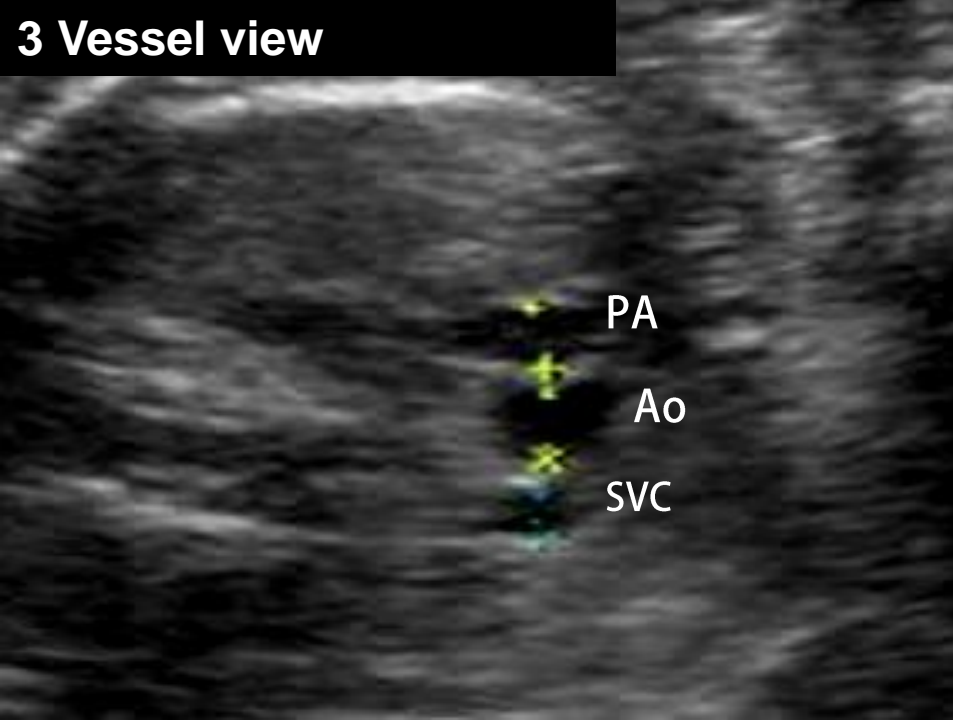


4 Chamber view

3 Vessel view



Color Doppler



Rescan at 31 weeks' gestation

Questions

1. What are the abnormal ultrasonographic findings?
2. What is the likely diagnosis?
3. What is the differential diagnosis?