

HKSUM CME program

February 2010

Case provided by Hye-Sung Won M.D

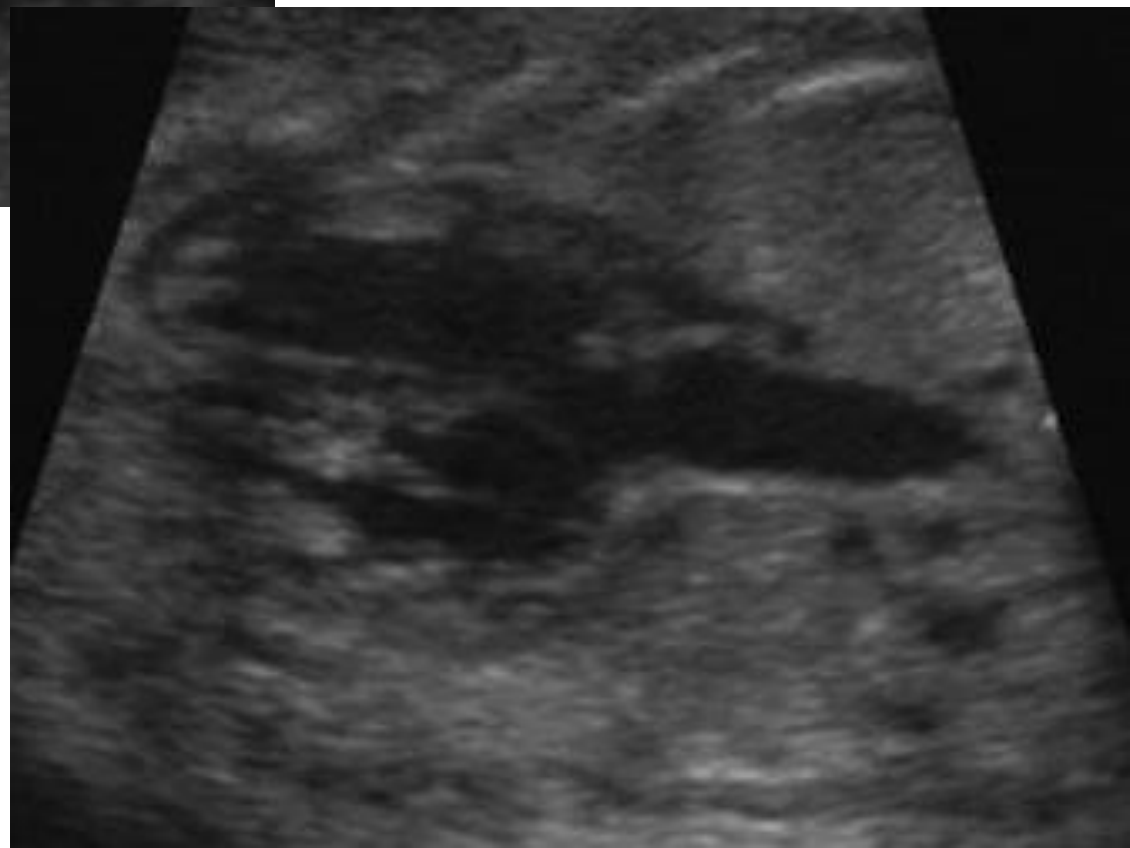
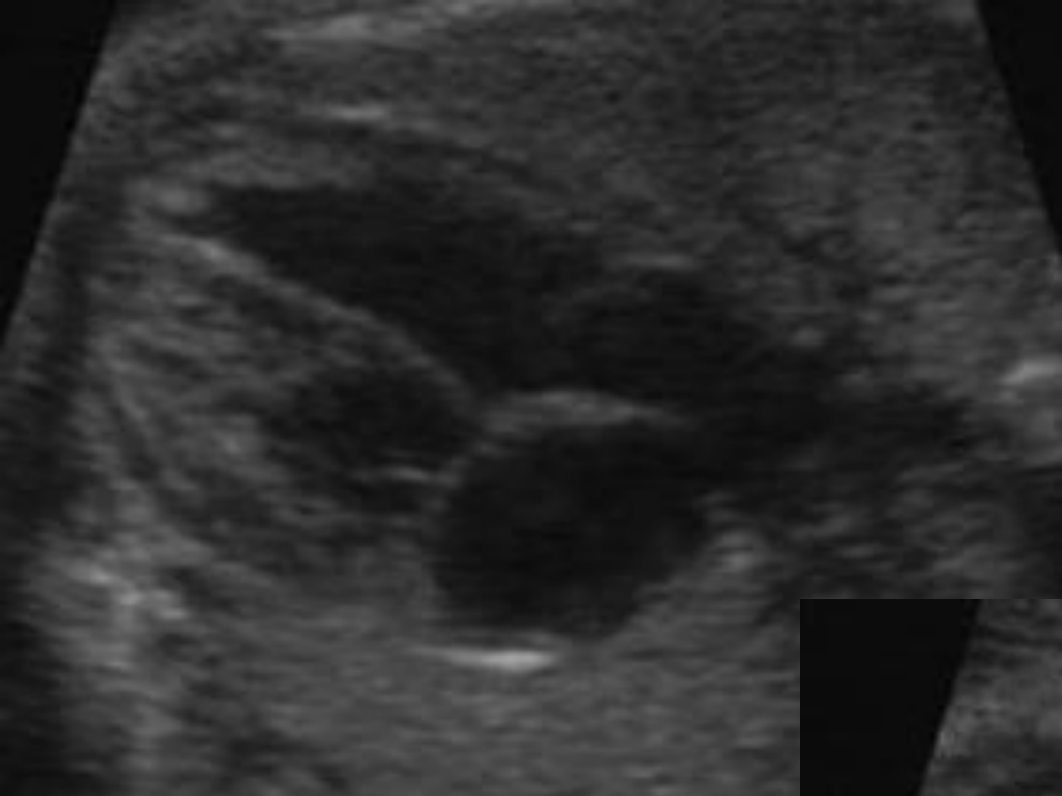
Department of Obstetrics and Gynecology, University of Ulsan College of Medicine,
Asan Medical Center, Seoul, Korea

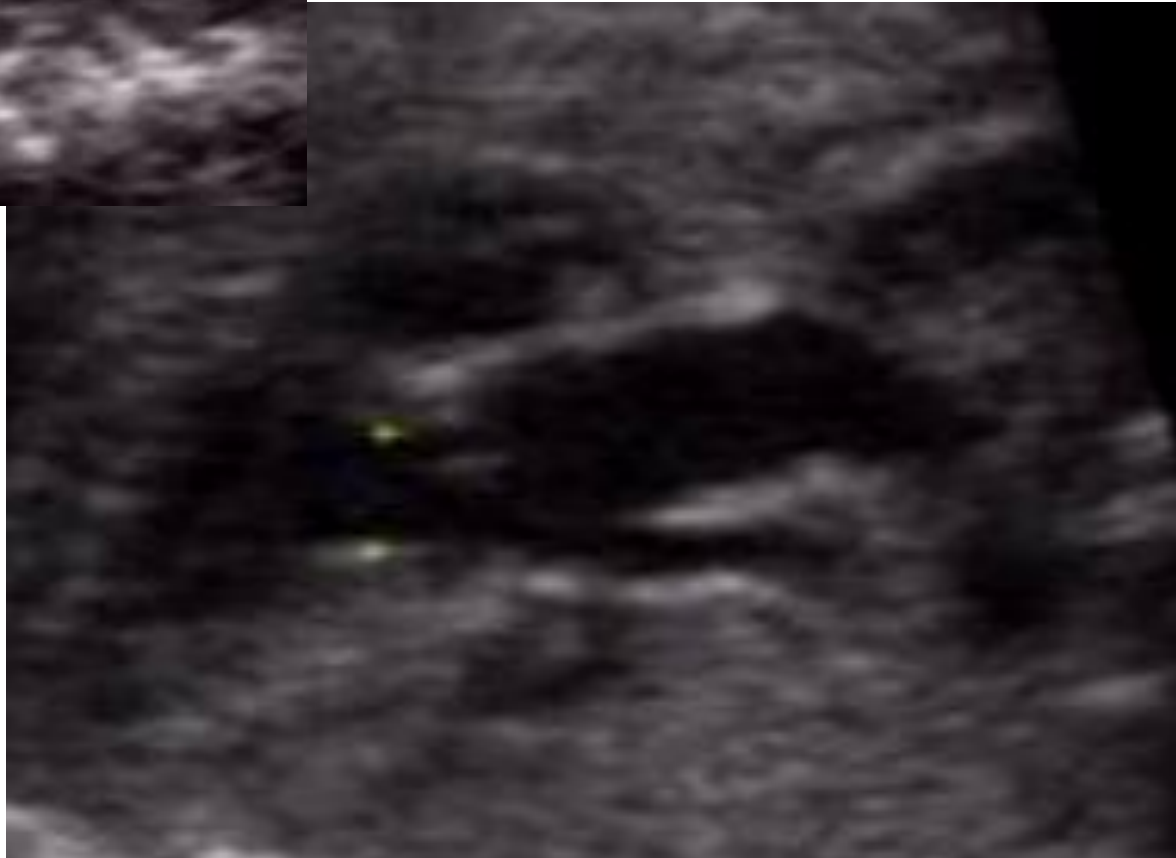
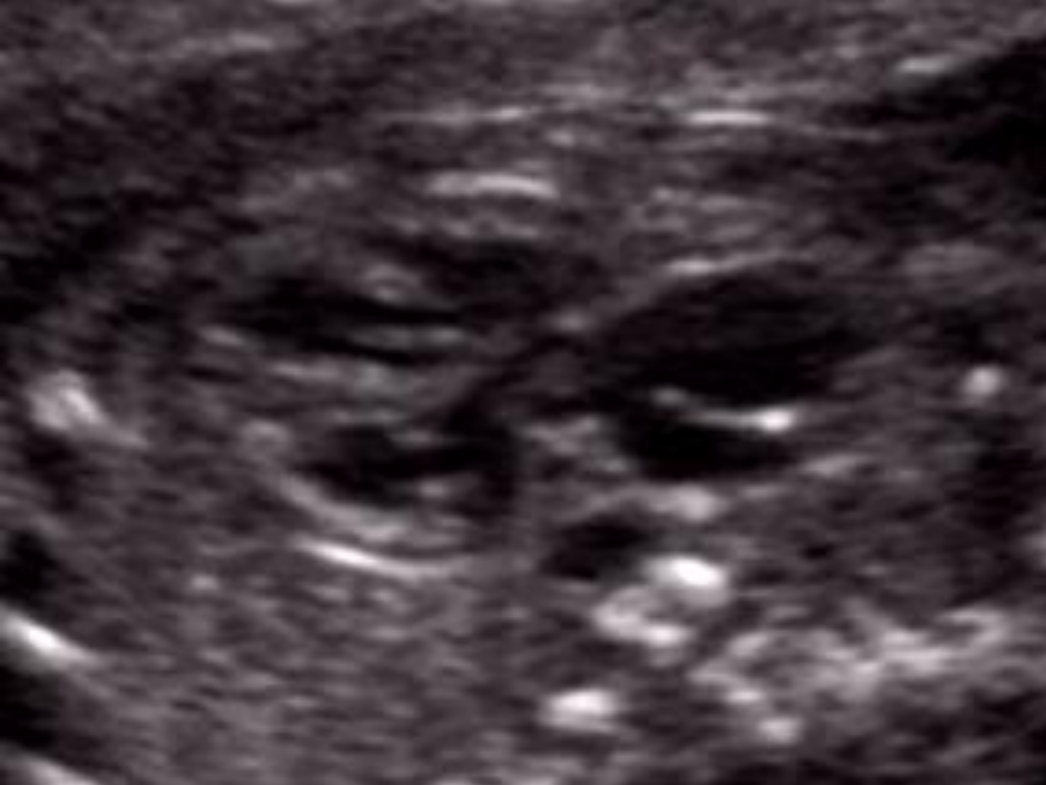Sponsored by Medison company

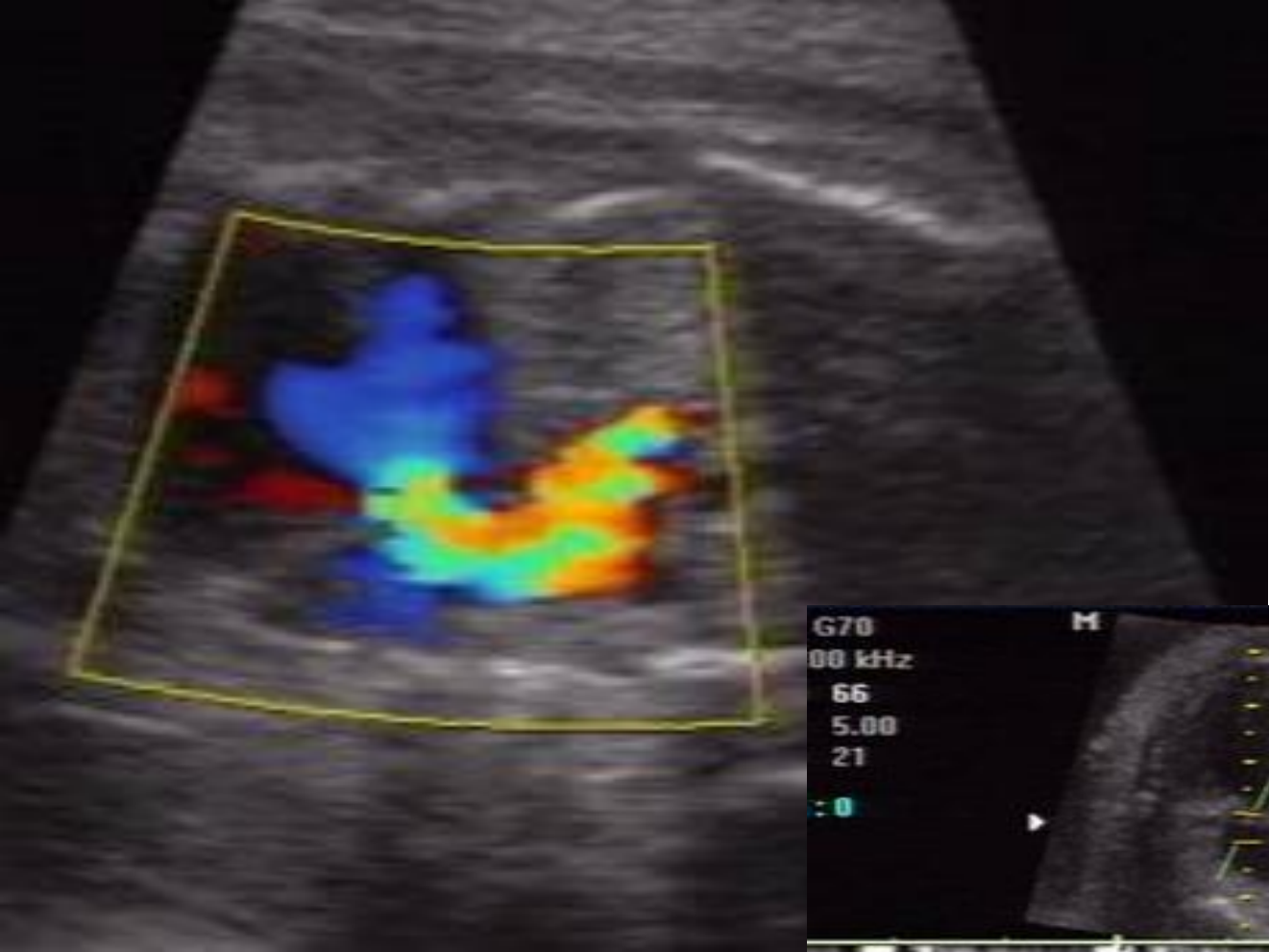Case

- **Ultrasound examination of fetal heart at 24 weeks' gestation**



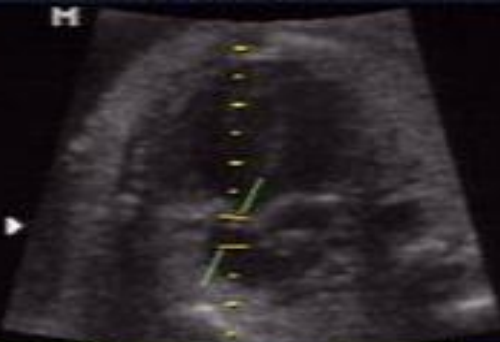



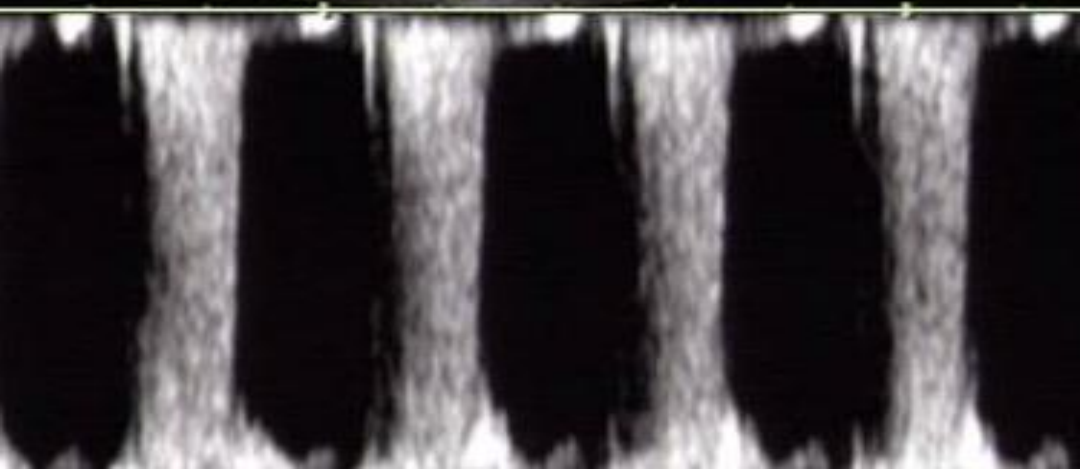


G70
00 kHz
66
5.00
21
: 0

M



[2D] G50 /
FAB /
HAF



Questions

1. What are the abnormal ultrasound findings?
2. What is the likely diagnosis?

Thank you