

HKSUM CME program

March 2010

Case provided by Prof. Hye-Sung Won M.D

Department of Obstetrics and Gynecology, University of Ulsan College of Medicine,
Asan Medical Center, Seoul, Korea

Sponsored by Medison company

Case

- **Ultrasound examination of fetal abdomen at 24 week's gestation.**

Figure A

Right kidney



Figure B

X



Right. kidney

Figure C

X



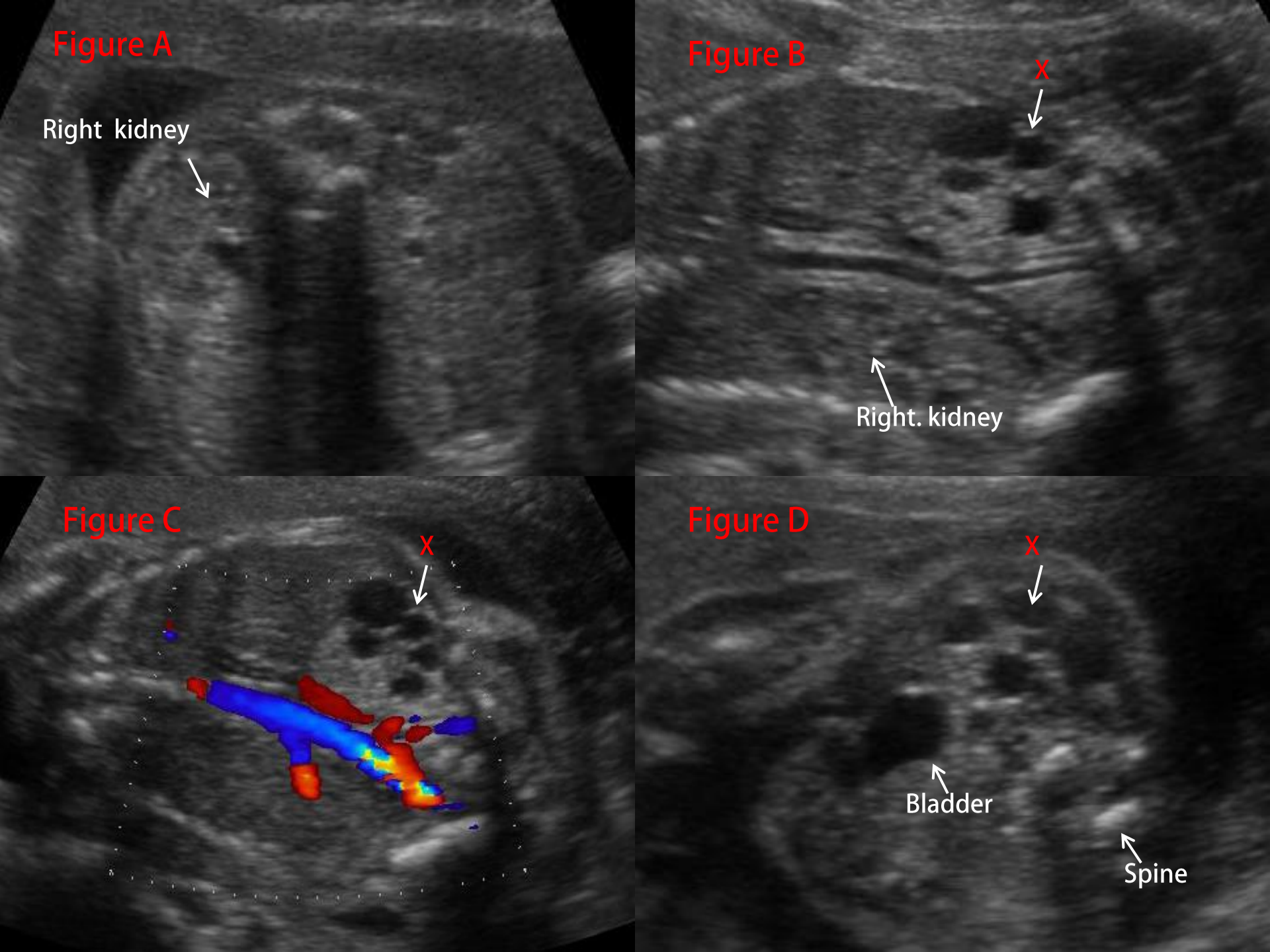
Figure D

X



Bladder

Spine



Questions

- What are the findings of figures A, B, C and D?
- What is the diagnosis?